

## Original Article

## Relationship Between Dynamic MRI Findings and the Prognostic Factors of Breast Cancer

## Meme Kanserinin Dinamik MRG Bulguları ile Prognostik Faktörleri Arasındaki İlişki

Hale Aydın<sup>1</sup>, Bahar Güner<sup>1</sup>, Işıl Esen Bostancı<sup>1</sup>, Almıla Coşkun Bilge<sup>1</sup>, Zarife Melda Bulut<sup>2</sup>, Bilgin Arıbaş<sup>1</sup>, Lütfi Doğan<sup>3</sup>, Mehmet Ali Gülçelik<sup>3</sup>

<sup>1</sup>Department of Radiology, Dr Abdurrahman Yurtaslan Ankara Oncology Training and Research Hospital, Ankara, Turkey

<sup>2</sup>Department of Pathology, Dr Abdurrahman Yurtaslan Ankara Oncology Training and Research Hospital, Ankara, Turkey

<sup>3</sup>Department of General Surgery, Dr Abdurrahman Yurtaslan Ankara Oncology Training and Research Hospital, Ankara, Turkey

## ABSTRACT

**Introduction:** The use of MR imaging in breast cancer is increasing. In recent years, MRI has been gaining use as a modality that can provide important information about breast cancer lesions. Our aim was to determine if any significant relationship existed between dynamic MRI findings and factors which are currently being used to establish prognosis.

**Methods:** Eighty-one patients with a diagnosis of invasive breast carcinoma and breast MRI were retrospectively reviewed and included in the study. Kinetic MRI features were determined on breast MR images, histopathological results were reviewed and prognostic factors were recorded.

**Results:** Thirty-five patients' initial enhancement was lower than fifty percent, while 18 patients were between fifty and one hundred percent and 28 patients higher than one hundred percent. Our study is one of the latter, we could not identify any significant relationships between initial enhancement characteristics and dynamic curve types with any of the analyzed prognostic factors.

**Discussion and Conclusion:** Although imaging can provide important data in the identification, diagnosis, and evaluation of many types of disease; imaging findings do not always correlate with patient clinic and prognosis. Up until now, studies on this matter have mostly found nothing of high significance; our study was no exception, however some of the data reported in this study can influence future studies.

**Keywords:** MRI, Breast imaging, Breast cancer

## ÖZET

**Giriş ve Amaç:** MR görüntülemenin meme kanserinde kullanımı artmaktadır. Son yıllarda MRG, meme kanseri lezyonları hakkında önemli bilgiler sağlayabilen bir yöntem olarak kullanılmaya başlanmıştır. Amacımız, dinamik MRG bulguları ile prognoz belirlemek için kullanılan faktörler arasında önemli bir ilişki olup olmadığını saptamaktır.

**Yöntem ve Gereçler:** İnvaziv meme kanseri tanısı ve meme MR görüntülemesi olan seksen bir hasta retrospektif olarak tarandı ve çalışmaya dahil edildi. Meme MR görüntülerinde kinetik MR özellikleri belirlendi ve histopatolojik sonuçları yeniden gözden geçirilerek prognostik faktörleri kaydedildi.

**Bulgular:** Kinetik MR özellikleri ilk faz kontrastlanma düzeyine göre gruplandı ve 35 hastada %50'nin altında, 18 hastada %50 ile %100 arasında ve 28 hastada %100'den fazlaydı. Çalışmamızda, analiz

edilen prognostik faktörlerin herhangi biri ile erken kontrastlanma özellikleri ve dinamik eğri türleri arasında herhangi bir anlamlı ilişki tespit edemedik.

**Tartışma ve Sonuç:** Görüntüleme birçok hastalık türünün tanısı, teşhisi ve değerlendirilmesinde önemli veriler sağlasa da görüntüleme bulguları her zaman hasta kliniği ve prognozu ile ilişkili değildir. Şimdiye kadar, bu konudaki çalışmalar çoğunlukla, çalışmamızla benzer şekilde anlamlı bir ilişki bulamadı, ancak çalışmamızda bildirilen bazı veriler gelecekteki çalışmaları etkileyebilir.

**Anahtar Kelimeler:** MRG, Meme görüntüleme, Meme kanseri

## Introduction

The most frequently diagnosed cancer among women worldwide is breast cancer; it is also the leader among deaths caused by cancer in women [1]. Breast cancer awareness and consequently the frequency of early diagnosis through effective screening and self-examination is on the rise [2,3]. Also the mortality rate of breast cancer has reduced in recent years [1]. This progress may be in part due to advancements in imaging modalities which are used in the screening and diagnosis of breast cancer. These imaging methods are: mammography (MMG), ultrasonography (USG), computed tomography (CT), positron emission tomography–CT (PET-CT), and magnetic resonance imaging (MRI) [4]. Other methods used for diagnosing breast cancer or supplementing a diagnosis are: pathologic evaluation of tumor biopsy (presence of malignant cells), breast cancer receptor testing, and genetic marker identification [5]. When breast cancer diagnosis is established, further evaluations are required to understand the extent of the disease and determine treatment path(s).

The determination of prognosis is important for informing the patient, deciding on the options for treatment and other medical/social decisions. Classical guidelines incorporate lymph node status and tumor size together with pathological findings such as histological type and grade of the cancer to determine prognosis [6,7]. The results of this approach are found to be significantly correlated with recurrence-free and overall survival [8]. Molecular biomarkers, from blood or biopsy

material, are another approach. The determination of various biomarkers such as Ki-67, cerbB2 (HER2 and sHER2), aromatase, osteopontin, and CEASCAM6 have been found to determine prognosis at different reliability levels [9]. Steroid hormone receptor (estrogen and progesterone receptors) expression measurements are also important for prognosis due to their influence on hormone therapy efficacy [10,11].

Magnetic resonance imaging (MRI), as previously stated, is one of the imaging modalities used in the diagnosis of breast cancer. It is also used as a screening tool in women who are at higher risk for breast cancer [12]. The use of contrast in dynamic MRI, namely dynamic contrast-enhanced MRI, has emerged as a very high sensitivity modality which is effective in the detection and staging of invasive breast cancer [13]. MRI determines the functional characteristics of the tumor, these characteristics were found to be an important addition to the diagnostic approach in breast cancer [14]. A significant relationship between MRI kinetic findings and prognosis may exist, identifying this relationship would improve the approach to breast cancer and may serve as an alternative method in determining prognosis.

We hypothesized that patients with poor prognostic factors will exhibit washout type (type 3) contrast enhancement pattern. The more aggressive malignant lesion will have more cell turnover. In addition, neovascularization is increased in the mass. Thus, we would expect the mass to lose contrast in a fast manner in the early phase (consistent with

type 3 curves). Furthermore, various studies associate tumor grade with tumor angiogenesis [15,16]. As tumor grade is one of the classical factors for breast cancer prognosis, determining the level of angiogenesis (via contrast-enhanced dynamic MRI) in the tumor may provide important prognostic data. Several studies have investigated the relationship between classical prognostic factors and kinetic MRI results [17-25], these studies yielded conflicting results.

Our aim was to determine if any relationship exists between kinetic MRI features and classical prognostic factors with a focus on dynamic curve types.

## Methods

The study was designed as a retrospective study of invasive breast cancer patients who had been treated at our hospital between 2015 and 2016. Ethical approval was obtained from local ethics committee. Additional approval was obtained from the hospital board as our institution is considered as a reference hospital for breast cancer (Decision number and date: 2010-04/1116 and 07.04.2021).

The MRI values and dynamic results of patients who had MRI indications and had undergone MRI which revealed they had BIRADS-4 or BIRADS-5 lesions were recorded by searching our MRI archive. Inclusion criteria were as follows. (1) Patient had to have a histologically proven invasive cancer of the breast, (2) patient had to have a dynamic MRI conducted for invasive breast cancer. Exclusion criteria were as follows. (1) History of other cancer, (2) having any chronic comorbid condition, (3) missing pathological parameters due to insufficient tissue material. A total of 98 patients were analyzed. Four of these patients who had metastasized stage-4 disease diagnosed with tru-cut biopsy were excluded due to insufficient tissue material for the

identification of all pathological parameters. A further 3 were excluded because their pathological examination revealed the tumors to be ductal carcinoma in-situ (DCIS). And 10 were excluded because of benign pathologic results. Thus, a final group of 81 patients were enrolled in the study.

## MR Imaging

MR imaging results were acquired with a 1.5 Tesla scanner (Signa HDx, 1.5 T, GE Healthcare) using a dedicated breast coil and evaluated according to breast imaging and reporting data system (BI-RADS) by three breast radiologists with at least 5-year experience in breast MRI evaluation. Images consisted of: axial T1-weighted fast spin echo imaging (TR/TE=400/8.8, a field of view (FOV) of 320 mm, a matrix of 448 x 224, number of excitations (NEX) of 1, and 5 mm slice thickness); axial STIR (TR/TE=6500/45, TI=150 ms, FOV of 320 mm, a matrix of 416x224, number of excitations (NEX) of 1, and 5 mm slice thickness); axial dynamic images with pre and post-contrast fat saturated gradient T1 sequences (TR/TE=4/1.5, a flip angle of 10°, FOV of 320 mm, a matrix of 350x350, NEX of 1, and 2.8 mm slice thickness). Images were taken once before contrast and 5 times after contrast injection with 80 second intervals. Contrast material was gadobutrol/gadopentetate dimeglumine with a dose of 0.1 mmol/kg. Re-evaluation of imaging data was performed when needed.

Region of interest (ROI) area was designated between 36-100 mm<sup>2</sup> and further calculations were performed automatically by the workstation. Formula used for initial enhancement calculation was: (Signal postcontrast–Signal initial)/ Signal initial × 100%). We divided our cases into three groups in regard to initial enhancement values (<50%, 50-100%, >100%) this grouping was previously performed by [25]. However, a consensus on this matter does not exist.

Determination of kinetic curve type was done according to post-initial enhancement data; type 1 is defined by stable increase of enhancement, type 2 is the formation of a plateau of signal intensity after contrast injection, type 3 is the stable decrease of enhancement in the post-initial phase [26].

### Histopathology

Pathological evaluations -according to the tumour, node and metastasis (TNM) classification- and prognosis determinations -according to the classical guidelines via antibody staining- were performed by certified pathologists. Tissue obtained in surgery was fixed in %10 formalin and was processed to paraffin blocks at 5 µm thickness; which was the routine protocol. Tumor type was determined by the WHO classification. Tumor grading (grade 1, 2, and 3) was accomplished by the modified Bloom-Richardson protocol. Lymph node involvement was assessed by the sentinel method. Positive lymph nodes were dissected. Lymphovascular invasion (LVI) was assessed by hematoxylin-eosin staining. Standardized protocols were used in the staining of Ki-67, estrogen and progesterone receptors, and C-erb B2 (Her2/neu) receptor from the invasive part of the tumor; and the assessment was done by calculating the percentage of stained cells.

### Statistical Analysis

All analyses were performed on SPSS v21. For the normality test, Shapiro-Wilk test was used. Continuous variables are given as mean ± standard deviation for normally distributed data and median (minimum – maximum) for non-normally distributed data. Comparisons between groups were made with one-way ANOVA for normally distributed data and Kruskal Wallis test for non-normally distributed data. Pairwise comparisons were made with Dunn's test. Categorical variables are given as frequency (percentage). Analysis

of categorical variables were made with Chi-square test.  $p \leq 0.05$  values were accepted as statistically significant.

### Results

We included 81 female patients into our study, median age was  $47.27 \pm 12.13$ . Sixty-three (77.8%) patients had invasive ductal carcinoma (IDC) while 9 (11.1%) patients had invasive lobular carcinoma (ILC). In addition, one of the patients were diagnosed with invasive cribriform carcinom, one invasive secretory carcinom, two mixed IDC + ILC, two invasive medullary carcinom, one tubular carcinom and two mucinous carcinom. When we evaluated tumor grades there were 11 (14.9%) patients with Grade 1, 29 (29.2%) patients with Grade 2 and 34 (45.9%) patients with Grade 3 tumor, while grading for 7 patients were missing. Forty-five (55.6%) patients had DCIS component while 10 (12.3%) had lobular carcinoma in situ (LCIS) component. Twenty patients had LVI and 4 (4.9%) patients received neoadjuvant chemotherapy.

When we made comparisons in regard to tumor grades, Ki-67 percentages were significantly higher in patients with Grade 3 tumor ( $p < 0.001$ ). There were no significant differences between these regarding age, ER (%) and PR (%). Also we found that 11 of the 15 (73.3%) patients with 3 C-erb B2 score had Grade 3 tumor. This result was also found to be significant ( $p = 0.011$ ) (Table 1).

We divided our patients into three groups regarding initial enhancement. Thirty-five patients' initial enhancement was lower than fifty percent, while 18 patients were between fifty and one hundred percent and 28 patients higher than one hundred percent. When we compared Ki-67, ER and PR values we found no significant difference between our groups (Figure 1). When we evaluated tumor types, 31 (49.2%) of the patients with IDC had lower than fifty percent initial enhancement while 5

Table 1. Patients' Characteristics Regarding Tumor Grade

	Grade 1 (n=11)	Grade 2 (n=29)	Grade 3 (n=34)	p
Age, mean $\pm$ SD	48.91 $\pm$ 10.78	48.66 $\pm$ 12.69	44.68 $\pm$ 12.25	0.370
Ki-67 (%), median (min - max)	8.00 (2.00 - 21.00) <sup>(a)</sup>	10.00 (2.00 - 80.00) <sup>(a)</sup>	40.00 (5.00 -95.00) <sup>(b)</sup>	<0.001**
ER (%), median (min - max)	90.00 (0.00 - 100.00)	90.00 (0.00 - 100.00)	80.00 (0.00 - 100.00)	0.078
PR (%), median (min - max)	60.00 (0.00 - 100.00)	80.00 (0.00 - 100.00)	65.00 (0.00 - 100.00)	0.396
Type, n (%)				
IDC	7 (12.3)	22 (38.6)	28 ( 49.1)	
ILC	1 (11.1)	5 (55.6)	3 (33.3)	0.320
Other	3 (37.5)	2 (25.0)	3 (37.5)	
C-erb-B2, n (%)				
0	10 (24.4)	14 (34.1)	17 (41.5)	
1	0 (0.0)	10 (76.9)	3 (23.1)	0.011*
2	0 (0.0)	2 (40.0)	3 (60.0)	
3	1 (6.7)	3 (20)	11 (73.3)	
Lenfovascular Invasion, n (%)				
Negative	6 (16.2)	15 (40.5)	16 (43.2)	0.291
Positive	1 (5.3)	6 (31.6)	12 (63.2)	
Neoadjuvant Chemotherapy, n (%)				
Absent	10 (14.1)	27 (38.0)	34 (47.9)	0.252
Present	1 (33.3)	2 (66.7)	0 (0.0)	

Same letter denotes the lack of statistically significant difference between groups

Ki-67 : Proliferation index ; ER: Estrogen receptor ; PR: Progesterone receptor ; C-erb-B2: Human epidermal growth factor receptor 2 ; IDC: Invasive ductal carcinoma ; ILC: Invasive lobular carcinoma

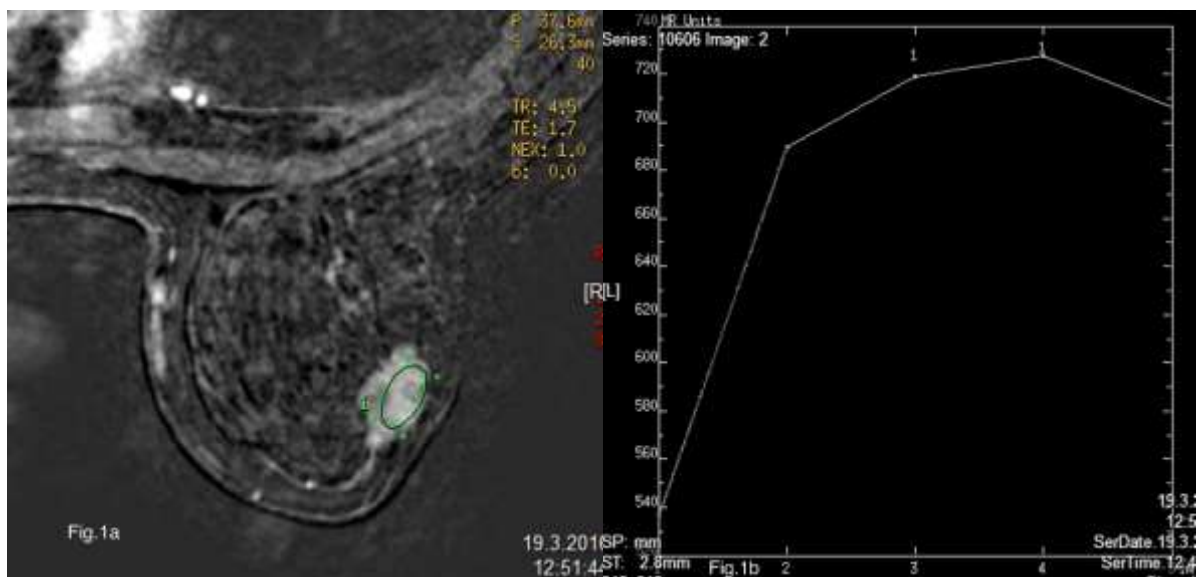


Figure 1a: Dynamic contrast enhanced breast MRI shows a mass with irregular margins in 37-year-old woman. Final pathology showed grade-2 invasive ductal carcinoma. Percentage of Ki-67 were 30%, estrogen and progesterone receptors were both 95%, and c-erb2 receptor score was 1 in the tumor.

Figure 1b: Kinetic curve analysis shows plateau patterns (type-2) on dynamic CE MR imaging.

Table 2. Patients' Characteristics Regarding Initial Enhancement

	<50% (n=35)	50% - 100% (n=18)	>100% (n=28)	p
Ki-67 (%), median (min - max)	35.00 (3.00 - 95.00)	25.00 (5.00 - 60.00)	20.00 (2.00 - 80.00)	0.069
ER (%), median (min - max)	90.00 (0.00 - 100.00)	90.00 (0.00 - 100.00)	90.00 (0.00 - 100.00)	0.806
PR (%), median (min - max)	70.00 (0.00 - 100.00)	50.00 (0.00 - 90.00)	80.00 (0.00 - 100.00)	0.272
Type, n (%)				
IDC	31 (49.2)	13 (20.6)	19 (30.2)	0.014*
ILC	1 (11.1)	5 (55.6)	3 (33.3)	
Other	3 (33.3)	0 (0.0)	6 (66.7)	
Tumor Grade				
Grade 1	4 (36.4)	1 (9.1)	6 (54.5)	0.454
Grade 2	13 (44.8)	8 (27.6)	8 (27.6)	
Grade 3	17 (50.0)	6 (17.6)	11 (32.4)	
C-erb-B2, n (%)				
0	15 (33.3)	11 (24.4)	19 (42.2)	0.375
1	6 (46.2)	3 (23.1)	4 (30.8)	
2	3 (60.0)	0 (0.0)	2 (40.0)	
3	11 (61.1)	4 (22.2)	3 (16.7)	
Lenfovacular Invasion, n (%)				
Negative	15 (37.5)	10 (25.0)	15 (37.5)	0.230
Positive	12 (57.1)	2 (9.5)	7 (33.3)	
Neoadjuvant Chemotherapy, n (%)				
Absent	32 (41.6)	18 (23.4)	27 (35.1)	0.362
Present	3 (75.0)	0 (0.0)	1 (25.0)	

Ki-67 : Proliferation index ; ER: Estrogen receptor ; PR: Progesterone receptor ; C-erb-B2: Human epidermal growth factor receptor 2 ; IDC: Invasive ductal carcinoma ; ILC: Invasive lobular carcinoma

Table 3. Patients' Characteristics Regarding Dynamic Types

	Type 1 (n=5)	Type 2 (n=40)	Type 3 (n=36)	p
Ki-67 (%), median (min - max)	18.00 (5.00 - 40.00)	21.00 (2.00 - 80.00)	30.00 (3.00 - 95.00)	0.221
ER (%), median (min - max)	90.00 (0.00 - 100.00)	90.00 (0.00 - 100.00)	90.00 (0.00 - 100.00)	0.702
PR (%), median (min - max)	90.00 (0.00 - 90.00)	75.00 (0.00 - 100.00)	50.00 (0.00 - 100.00)	0.356
Initial Enhancement, n (%)				
<50%	0 (0.0)	7 (20.0)	28 (80.0)	<0.001**
50% - 100%	0 (0.0)	13 (72.2)	5 (27.8)	
>100%	5 (17.9)	20 (71.4)	3 (10.7)	
Type, n (%)				
IDC	3 (4.8)	28 (44.4)	32 (50.8)	0.061
ILC	2 (22.2)	6 (66.7)	1 (11.1)	
Other	0 (0.0)	6 (66.7)	3 (33.3)	
Tumor Grade				
Grade 1	2 (18.2)	5 (45.5)	4 (36.4)	0.570
Grade 2	1 (3.4)	14 (48.3)	14 (48.3)	
Grade 3	2 (5.9)	17 (50.0)	15 (44.1)	
C-erb-B2, n (%)				
0	4 (8.9)	26 (57.8)	15 (33.3)	0.318
1	0 (0.0)	6 (46.2)	7 (53.8)	
2	0 (0.0)	1 (20.0)	4 (80.0)	
3	1 (5.6)	7 (38.9)	10 (55.6)	
Lenfovacular Invasion, n (%)				
Negative	3 (7.5)	21 (52.5)	16 (40.0)	0.772
Positive	2 (9.5)	9 (42.9)	10 (47.6)	
Neoadjuvant Chemotherapy, n (%)				
Absent	4 (5.2)	40 (51.9)	33 (42.9)	0.068
Present	1 (25.0)	0 (0.0)	3 (75.0)	

Ki-67 : Proliferation index ; ER: Estrogen receptor ; PR: Progesterone receptor ; C-erb-B2: Human epidermal growth factor receptor 2 ; IDC: Invasive ductal carcinoma ; ILC: Invasive lobular carcinoma

Table 4. Patients' Characteristics when Grouped as Washout and Others

	Type 1 and 2 (n=45)	Washout (n=36)	p
Ki-67 (%), median (min - max)	20.50 (2.00 - 80.00)	30.00 (3.00 - 95.00)	0.113
ER (%), median (min - max)	90.00 (0.00 - 100.00)	90.00 (0.00 - 100.00)	0.466
PR (%), median (min - max)	80.00 (0.00 - 100.00)	50.00 (0.00 - 100.00)	0.184
Initial Enhancement, n (%)			
<50%	7 (20.0)	28 (80.0)	
50% - 100%	13 (72.2)	5 (27.8)	<0.001**
>100%	25 (89.3)	3 (10.7)	
Type, n (%)			
IDC	31 (49.2)	32 (50.8)	
ILC	8 (88.9)	1 (11.1)	0.063
Other	6 (66.7)	3 (33.3)	
Tumor Grade			
Grade 1	7 (63.6)	4 (36.4)	
Grade 2	15 (51.7)	14 (48.3)	0.793
Grade 3	19 (55.9)	15 (44.1)	
C-erb-B2, n (%)			
0	30 (66.7)	15 (33.3)	
1	6 (46.2)	7 (53.8)	
2	1 (20.0)	4 (80.0)	0.103
3	8 (44.4)	10 (55.6)	
Lenfovacular Invasion, n (%)			
Negative	24 (60.00)	16 (40.0)	
Positive	11 (52.4)	10 (47.6)	0.765
Neoadjuvant Chemotherapy, n (%)			
Absent	44 (51.9)	33 (42.9)	
Present	1 (25.0)	3 (75.0)	0.318

Ki-67 : Proliferation index ; ER: Estrogen receptor ; PR: Progesterone receptor ; C-erb-B2: Human epidermal growth factor receptor 2 ; IDC: Invasive ductal carcinoma ; ILC: Invasive lobular carcinoma

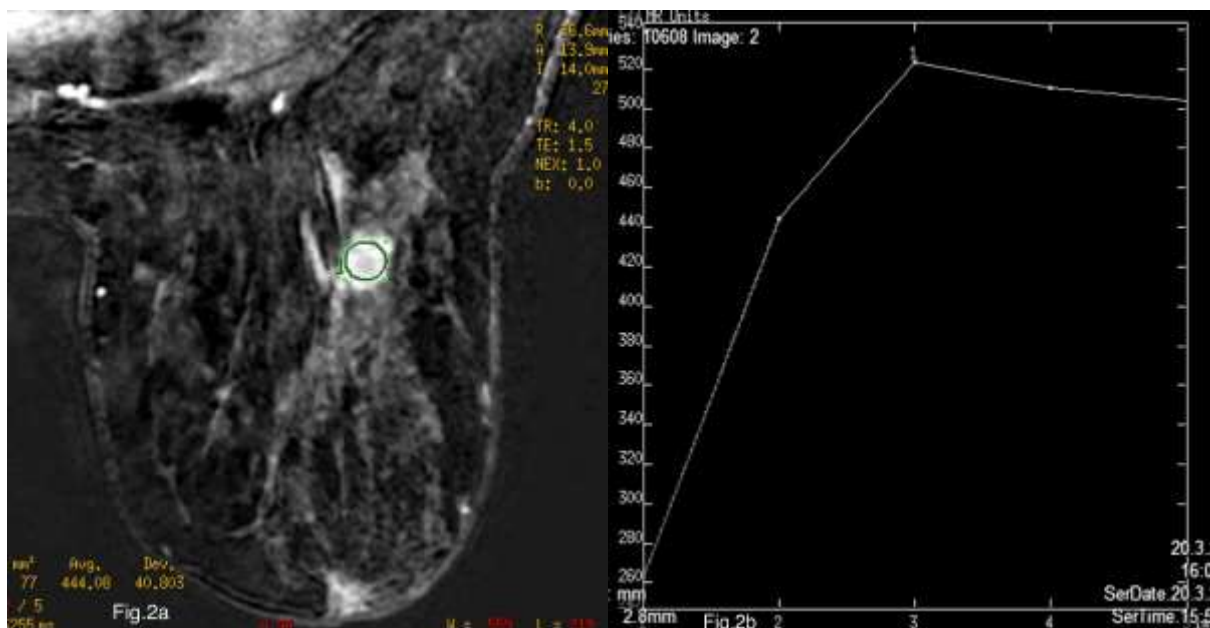


Fig.2a: Dynamic contrast enhanced breast MRI shows a mass with irregular margins in 53-year-old woman. Final pathology showed grade-3 invasive ductal carcinoma. Percentage of Ki-67 were 50%, estrogen and progesterone receptors were 50% and 70% respectively, and c-erb-b2 receptor score was 3 in the tumor.

Fig.2b: Kinetic curve analysis shows plateau patterns (type-2) on dynamic CE MR imaging.

(55.6%) of the patients with ILC had between fifty and one hundred percent initial enhancement. This result was also found to be significant ( $p=0.014$ ) (Table 2).

When we evaluated dynamic types; 5 (6.2%) patients had Type 1 curve, 40 (49.4%) patients had Type 2 curve and 36 (44.4%) patients had Type 3 curve. When we compared our variables between curve type groups we found that all of the patients with Type 1 curve had larger than one hundred percent initial enhancement and 28 of the 36 (77.8%) patients with Type 3 curve had lower than fifty percent initial enhancement ( $p<0.001$ ). There was no significant difference between our groups regarding other variables (Table 3).

Lastly, we evaluated washout type curves specifically. Which was done by divided the patients into two groups; (1) washout type curve (type 3) and (2) the other curve types (type 1 and 2). This evaluation was performed because a main focus of our hypotheses was that washout type curve (type 3) may have a higher association with prognostic factors. We found initial enhancement was significantly different between groups (as was found previously); however, we again found no significant relationship between any prognostic factors and washout type curve (Figure 2) (Table 4).

## Discussion

We aimed to identify any relationship between dynamic MRI findings (with a focus on washout type curve) and factors that affect prognosis in invasive breast cancers. Currently, tumor size and type, histological grade, lymph node status, LVI, steroid receptor (estrogen and progesterone) and human epidermal growth factor receptor expressions, and proliferation markers such as Ki-67 are accepted as important prognosis determining/affecting factors.

In MRI evaluation, tumor margin and its enhancement curve characteristics are accepted to be the most important features in the characterization of breast tumors [27]. Lack of enhancement is reported to have an 88-96% negative predictive value (NPV) for malignancy [28,29]. However, various studies report the enhancement evaluation to be problematic; in a multi-institutional study, 45% of lesions that were found to be malignant were actually reported as having persistent enhancement kinetics [28]. When attention is shifted to curve characteristics, type 2 and 3 curves are reported by some to be associated with malignancy [27]. On the other hand, the ability of diffusion imaging in characterizing microvascular structures has been shown to be important in the evaluation of breast cancer [19,22,30,31]. However, current studies focusing on kinetic evaluation for tumor characterization are rare and present conflicting results. We aimed to identify if any association existed between prognostic factors and enhancement and dynamic MRI findings.

## Tumor Grade

As tumor grade is one of the classical prognostic factors, any relationship between histopathological tumor grade and imaging findings would affect the use of imaging modalities in breast cancer diagnosis, screening and evaluation.

When patients were grouped in regard to initial enhancement characteristics (<50%, 50-100%, and >100%), we found no significant difference in tumor grade between groups. Also, no relationship was found when grouping was done in regard to dynamic types (type 1, 2, and 3). Lastly, grouping patients into two (washout type curve, and others) also yielded no significant differences. Only a few studies have reported a minor correlation between grade and enhancement characteristics [22,24,32]. Belli et al. reported



that grade 1 tumors had significantly higher mean apparent diffusion coefficient in comparison to grade 2 and 3 tumors. On the other hand, various studies report a lack of correlation between grade and kinetic MRI findings [33-35], including a 128-patient retrospective study by Baltzer et al. [36]. Our results concur with the latter group of literature.

A variety of explanations may exist for these conflicting results, including a lack of standardization in the grouping and evaluation of enhancement. However, in our study, the low number of grade 1 tumors (11, 13.5%) in comparison to grade 2 and 3 tumors (70, 86.5%) may have affected our results. Also, for dynamic evaluation, type 1 curve group consisted of only five cases which may have had a similar effect in the evaluation of dynamic types.

#### Ki-67 Index

Nuclear antigen Ki-67 is accepted as an accurate marker for cell proliferation. It is significantly correlated with mitotic activity. Ki-67 is reported as a percentage; called the Ki-67 index. A value above 20% indicates high proliferation and is associated with poor prognosis [37,38].

In our study, we found Ki-67 levels to be significantly higher in grade 3 tumors ( $p < 0.001$ ), no such difference was found between grade 1 and 2 tumors. When tumors were grouped according to initial enhancement values and dynamic types, we found no significant difference in Ki-67 values between groups. Also, no significant relationship with Ki-67 values and washout type was found.

Chang et al. also found no significant relationship between curve pattern and Ki-67 level. They reported peak time was the only factor correlated with Ki-67 value [18]. Choi et al. found that Ki-67 index positive invasive ductal cancer cases had a significantly lower

apparent diffusion coefficient (ADC) value compared to negative cases [6]. However, this finding may be due to the fact that malignant tumors (which have higher Ki-67 levels) show a significantly lower ADC value in comparison to benign tumors [39]. Another study, by Alduk et al., also reported that they found no relationship between Ki-67 and MRI features [40].

#### Estrogen and Progesterone Receptor Expression

As previously stated, estrogen and progesterone receptor (ER and PR, respectively) expression is an important factor for breast cancer prognosis; especially when hormone therapy is considered [41]. Patients who present with ER positive tumors are shown to have longer disease-free and overall survival time [42]. The nature and effects of PR and ER expression can shed light on what we can expect in MRI imaging. Some studies report that ER expression is related to angiogenic pathway inhibition which results in diffusion decrease [37,43]. Another effect of ER positivity is reported to be increase in cellularity [44]. When these two factors are taken into account while keeping in mind that ER expression also impacts PR expression, we can come to the conclusion that ER and PR expressions may influence initial enhancement and dynamic MRI results. However, we found no difference between ER or PR expression in regard to initial enhancement groups and dynamic types.

Various studies that aimed to identify a relationship between ER expression and MRI features found conflicting results. Some state that ER negative tumors show more malignant enhancement characteristics [30,36,45]; while others do not support this finding [18,33,40]. When PR expression was assessed, Chang et al. found a lack of relationship between curve type and PR expression [18], as did others [40]. However, Baltzer et al. reported initial

enhancement to be correlated with PR expression [36].

Comparing studies in this regard is difficult as receptor positivity heavily effects treatment paths and the increased use of MRI in higher risk patients may result in bias in patient selection.

#### C-erb B2 Expression

C-erb B2 (or HER2/neu) overexpression is widely accepted as a factor for poor prognosis [46]. Its expression is inversely correlated with ER expression [46,47]. ER expression is indicative of good prognosis, and C-erb B2 is indicative of poor prognosis. In our study -as stated above- we found no relationship between ER expression and MRI features; thus a lack of relationship between C-erb B2 and the same MRI features was expected. After analysis we found no relationship between C-erb B2 expression and initial enhancement characteristics or dynamic curve types which concurred with our in-study expectation. Chang et al. in their study focusing on curve patterns also found no relationship. However, they found peak time to be correlated with C-erb B2 expression.

#### Lymphovascular Invasion

There is limited data in literature on the relationship between LVI and MRI features. Alduk et al., in their study of 114 cases of invasive ductal carcinoma, analyzed the relationship between prognostic factors and MRI findings. They reported that a significant relationship between LVI and initial enhancement existed, but failed to find any such relationship in regard to curve type [40]. We found no significant relationship between LVI and either enhancement or curve type.

#### Strengths and Limitations

Our study has various strengths. Firstly, the number of patients included were 81; a number which matches previous studies. Secondly, most of the major prognostic

factors of invasive breast cancers were assessed in our study; thus comparisons with dynamic MRI findings (which were re-evaluated when necessary) were done for all of these factors. Thirdly, we grouped our patients in regard to tumor grade, initial enhancement, and dynamic curve types (also washout vs others) which gave a thorough understanding of the analyses made. Initial enhancement grouping was done according to a previous study (a consensus on this matter does not exist); which makes comparison of studies easier.

There are several limitations to our study. First, this study is based on patients from single center. Thus, the distribution of patients involved in our study group may not be homogeneous. However, our hospital is a regional reference hospital for breast cancer which results in the referring of many cases to us from other hospitals; which would increase homogeneity. Nevertheless, a single-center study may be considered as a limitation. Secondly, the morphological findings of MRI results were not evaluated in our study whereas other studies included morphological findings in their analyses. This may be seen as a limitation; however, our study was focused on the dynamic findings (especially washout curve type) and enhancement characteristics of breast cancer and their comparison with prognostic factors; thus the exclusion of morphological findings did not affect our evaluation.

Although literature on this topic is yet to expand; current studies that report significant relationships can be considered few and far between. Especially curve type and initial-enhancement focused studies point to a lack of association. However, when current literature is reviewed; we see a few important problems on this topic: The lack of consensus for the categorization of dynamic MRI data, differences in operator and/or evaluator evaluations, and variance in study methodologies to the point of incompatibility

between results. If these problems were to be addressed, studies with more data may be performed and comparisons between studies can be made.

Contrast-enhanced dynamic MRI is currently an important imaging tool in the evaluation of invasive breast cancer. The imaging findings can help in identifying important characteristics of the tumor; thus the evaluation of these findings in regard to their relationship with prognostic factors could have yielded important results and changed the way imaging modalities are utilized in breast cancer. However, in our study, neither enhancement characteristics nor dynamic

findings were found to be associated with prognostic factors. However, this does not mean that imaging findings are in no way related to patient prognosis; future studies that analyze the relationship between MRI findings and patients' follow-up and survival data are needed to identify direct relationships. Another important matter that needs to be clarified in future studies is the grouping of initial enhancement characteristics. Studies vary in the grouping and utilization of enhancement data; which results in inability to compare study findings with each other. Thus, a first step in enhancement evaluation may be to identify medically relevant enhancement cut-points.

## References

1. Organization, W.H., International Agency For Research on Cancer GLOBOCAN 2012: estimated cancer incidence, mortality and prevalence worldwide in 2012.
2. Kocaoz S, Özçelik H, Talas MS, et al. The Effect of Education on the Early Diagnosis of Breast and Cervix Cancer on the Women's Attitudes and Behaviors Regarding Participating in Screening Programs. *J Cancer Educ*; 2018; 33(4):821-832.
3. O'Mahony M, Comber H, Fitzgerald T, et al. Interventions for raising breast cancer awareness in women. *Cochrane Database Syst Rev*, 2017 10;2:CD011396.
4. Karellas A, Vedantham S. Breast cancer imaging: A perspective for the next decade. *Medical Physics*, 2008; 35(11): 4878–4897.
5. Hoskins WJ. Principles and practice of gynecologic oncology. 2005: Lippincott Williams & Wilkins.
6. Choi SY, Chang YW, Park HJ, Kim HJ, Hong SS, Seo DY. Correlation of the apparent diffusion coefficient values on diffusion-weighted imaging with prognostic factors for breast cancer. *Br J Radiol*. 2012; 85(1016): e474–e479.
7. Shen J, Hunt KK, Mirza NQ, et al. Intramammary lymph node metastases are an independent predictor of poor outcome in patients with breast carcinoma. *Cancer*, 2004 15;101(6):1330-7.
8. Muftah AA, Aleskandarany MA, Ellis IO, Rakha EA. Molecular-Based Diagnostic, Prognostic and Predictive Tests in Breast Cancer, in *Precision Molecular Pathology of Breast Cancer*. 2015, Volume 10; Springer.177-195.
9. Kutomi G, Mizuguchi T, Satomi F, et al. Current status of the prognostic molecular biomarkers in breast cancer: A systematic review. *Oncol Lett*, 2017; 13(3):1491-1498.
10. Brouckaert O, Paridaens R, Floris G, Rakha E, Osborne K, Neven P. A critical review why assessment of steroid hormone receptors in breast cancer should be quantitative. *Ann Oncol*, 2013;24(1):47-53.
11. Howell A, Barnes DM, Harland RN, et al. Steroid-hormone receptors and survival after first relapse in breast cancer. *Lancet*, 1984. 1(8377):588-91.
12. Mainiero MB, Lourenco A, Mahoney MC, et al. ACR Appropriateness Criteria Breast Cancer

- Screening. *J Am Coll Radiol*, 2016; 13(11S):R45-R49.
13. Beran L, Liang W, Nims T, Paquelet J, Sickle-Santanello B. Correlation of targeted ultrasound with magnetic resonance imaging abnormalities of the breast. *The American Journal of surgery*, 2005; 190(4):592-594.
  14. Rahbar H, Partridge SC. Multiparametric MR Imaging of Breast Cancer. *Magn Reson Imaging Clin N Am*, 2016; 24(1):223-38.
  15. Folkman J. What is the evidence that tumors are angiogenesis dependent? *J Natl Cancer Inst*, 1990; 82(1):4-6.
  16. Weidner N, Semple JP, Welch WR, Folkman J. Tumor angiogenesis and metastasis--correlation in invasive breast carcinoma. *N Engl J Med*, 1991; 324(1):1-8.
  17. Buadu LD, Murakami J, Murayama S, et al. Patterns of peripheral enhancement in breast masses: correlation of findings on contrast medium enhanced MRI with histologic features and tumor angiogenesis. *JCAT, Journal of computer assisted tomography*, 1997; 21(3):421-430.
  18. Chang YW, Kwon KH, Choi DL, et al. Magnetic resonance imaging of breast cancer and correlation with prognostic factors. *Acta Radiologica*, 2009. 50(9):990-998.
  19. Jinguji M, Kajiya Y, Kamimura K, et al. Rim enhancement of breast cancers on contrast-enhanced MR imaging: relationship with prognostic factors. *Breast Cancer*, 2006. 13(1):64-73.
  20. Lee SH, Cho N, Kim SJ, et al. Correlation between high resolution dynamic MR features and prognostic factors in breast cancer. *Korean J Radiol*, 2008; 9(1):10-18.
  21. Montemurro F, Martincich L, Sarotto I, et al. Relationship between DCE-MRI morphological and functional features and histopathological characteristics of breast cancer. *Eur Radiol*, 2007. 17(6):1490-1497.
  22. Mussurakis S, Buckley D, Horsman A. Dynamic MR imaging of invasive breast cancer: correlation with tumour grade and other histological factors. *Br J Radiol*, 1997. 70(833):446-451.
  23. Teifke A, Behr O, Schmidt M, et al. Dynamic MR imaging of breast lesions: Correlation with microvessel distribution pattern and histologic characteristics of prognosis 1. *Radiology*, 2006; 239(2):351-360.
  24. Tuncbilek N, Karakas HM, Okten OO. Dynamic magnetic resonance imaging in determining histopathological prognostic factors of invasive breast cancers. *Eur J Radiol*, 2005; 53(2):199-205.
  25. Vassiou K, Kanavou T, Vlychou M, Poultsidi AA. Morphological and kinetic characteristics of dynamic contrast-enhanced MRI (DCE-MRI) correlated with histopathological factors of breast cancer: A potential prognostic role of breast MRI? *European Journal of Radiography*, 2009. 1(4):124-132.
  26. Baum F, Fischer U, Vosschenrich R, Grabbe E. Classification of hypervascularized lesions in CE MR imaging of the breast. *Eur Radiol*, 2002; 12(5):1087-92.
  27. Macura KJ, Ouwerkerk R, Jacobs MA, Bluemke DA. Patterns of enhancement on breast MR images: interpretation and imaging pitfalls 1. *Radiographics*, 2006; 26(6):1719-1734.
  28. Schnall MD, Blume J, Bluemke DA, et al. Diagnostic architectural and dynamic features at breast MR imaging: multicenter study 1. *Radiology*, 2006; 238(1):42-53.
  29. Nunes LW, Schnall MD, Orel SG. Update of Breast MR Imaging Architectural Interpretation Model 1. *Radiology*, 2001. 219(2):484-494.
  30. Szabo BK, Aspelin P, Wiberg MK, Bone B. Dynamic MR imaging of the breast. Analysis of kinetic and morphologic diagnostic criteria. *Acta Radiologica*, 2003; 44(4):379-386.
  31. Partridge SC, DeMartini WB, Kurland BF, Eby PR, White SW, Lehman CD. Quantitative diffusion-weighted imaging as an adjunct to conventional breast MRI for improved positive predictive value. *AJR Am J Roentgenol*, 2009; 193(6):1716-1722.
  32. Bone B, Aspelin P, Bronge B, Veress B. Contrast-enhanced MR imaging as a prognostic indicator of breast cancer. *Acta Radiologica*, 1998. 39(3):279-284.
  33. Stomper PC, Herman S, Klippenstein DL, et al. Suspect breast lesions: findings at dynamic

- gadolinium-enhanced MR imaging correlated with mammographic and pathologic features. *Radiology*, 1995; 197(2):387-395.
34. Fischer U, Kopka L, Brinck U, Korabiowska M, Schauer A, Grabbe E. Prognostic value of contrast-enhanced MR mammography in patients with breast cancer. *Eur Radiol*, 1997. 7(7):1002-1005.
35. Gilles R, Guinebretiere JM, Lucidarme O, et al. Nonpalpable breast tumors: diagnosis with contrast-enhanced subtraction dynamic MR imaging. *Radiology*, 1994; 191(3):625-631.
36. Baltzer PAT, Vag T, Dietzel M, et al. Computer-aided interpretation of dynamic magnetic resonance imaging reflects histopathology of invasive breast cancer. *Eur Radiol*, 2010; 20(7):1563-1571.
37. Kim SH, Cha ES, Kim HS, et al. Diffusion-weighted imaging of breast cancer: Correlation of the apparent diffusion coefficient value with prognostic factors. *J Magn Reson Imaging*, 2009; 30(3):615-620.
38. Donegan WL. Tumor-related prognostic factors for breast cancer. *CA Cancer J Clin*, 1997; 47(1):28-51.
39. Hatakenaka M, Soeda H, Yabuuchi H, et al. Apparent diffusion coefficients of breast tumors: clinical application. *Magn Reson Med Sci*, 2008. 7(1):23-29.
40. Alduk AM, Brcic I, Podolski P, Prutki M. Correlation of MRI features and pathohistological prognostic factors in invasive ductal breast carcinoma. *Acta Clinica Belgica*, 2017; 72:5,306-312.
41. Bauer KR, Brown M, Cress RD, Parise CA, Caggiano V. Descriptive analysis of estrogen receptor (ER)-negative, progesterone receptor (PR)-negative, and HER2-negative invasive breast cancer, the so-called triple-negative phenotype. *Cancer*, 2007; 109(9):1721-1728.
42. Stewart JF, Rubens RD, Millis RR, King RJ, Hayward JL. Steroid receptors and prognosis in operable (stage I and II) breast cancer. *EJC*, 1993; 19(10):1381-1387.
43. Ludovini V, Sidoni A, Pistonla L, et al. Evaluation of the prognostic role of vascular endothelial growth factor and microvessel density in stages I and II breast cancer patients. *Breast Cancer Res Tr*, 2003; 81(2):159-68.
44. Addis ME, Mahalik JR. Men, masculinity, and the contexts of help seeking. *Am Psychol*. 2003 58(1):5.
45. Chen JH, Baek HM, Nalcioglu O, Su MY. Estrogen receptor and breast MR imaging features: a correlation study. *J Magn Reson Imaging*, 2008; 27(4):825-833.
46. Tsutsui S, Ohno S, Murakami S, Hachitanda Y, Oda S. Prognostic value of c-erbB2 expression in breast cancer. *J Surg Oncol*, 2002; 79(4):216-23.
47. Bezwoda WR. C-erb-B2 expression and response to treatment in metastatic breast cancer. *Med Oncol*, 2000 17(1):22-8.

Corresponding author e-mail: halemaydin@gmail.com

Orcid ID:

Hale Aydın 0000-0002-4789-4641

Bahar Güner 0000-0002-9855-6992

Işıl Esen Bostancı 0000-0001-6026-0830

Almila Coşkun Bilge 0000-0002-0371-4194

Zarife Melda Bulut 0000-0002-0064-3634

Bilgin Arıbaş 0000-0001-8218-1359

Lütfi Doğan 0000-0002-3834-0911

Mehmet Ali Gülçelik 0000-0002-8967-7303

Doi: 10.5505/aot.2021.60252